



PATIENT

Mojo Romano

SPECIES

Feline

BREED

DSH

SEX

Male Neutered

AGE

6 years

WEIGHT

15.06lbs

INTERPRETED BY

Maggie Machen
Lamy, DVM
DACVIM (Cardiology)

PRESENTING CLINICAL SIGNS

History: Recheck echo. History mild-moderate left atrial enlargement on prior echocardiograms. Presently, Mojo is scheduled for a dental with otic mass removal in the near future. He is eating well with normal activity level. On exam: NSR, grade III/VI murmur noted on sternum, PSS, lung fields slightly harsh on inspiration, compressible thorax, mm pink, moist, CRT<2. BP: 110-120mmHg. Currently, on flovent, albuteral. *No sedation for study.
-Pertinent previous echo findings (11/29/22 MML): LA 1.5 cm, LA:Ao 1.5, IVS 0.52 cm, PW 0.58 cm.

ECHOCARDIOGRAM FINDINGS

2D, m-mode, color flow and Doppler imaging is available.
Left ventricle: The LV diameter is normal with adequate myocardial function. The LV wall thicknesses are borderline hypertrophied. There is mild fibrosis of the endocardium. The endocardium appears mildly remodeled. The papillary muscles appear hyperechoic and normal in dimension.
Left atrium: The left atrium is mild to moderately enlarged. No obvious smoke or thrombi seen.
Mitral valve: The mitral valve is normal in structure and mobility. No obvious systolic anterior motion is seen. No MR.
Aortic valve/aorta: The aortic valve is normal in morphology and mobility. Normal aortic outflow velocity; laminar flow. No aortic insufficiency.
Right ventricle: Normal right ventricular diameter and morphology indicating no overt evidence of pulmonary arterial hypertension.
Right atrium: The right atrium is normal in dimension.
Tricuspid valve: The tricuspid valve appears normal with no tricuspid regurgitation.
Pulmonic valve/pulmonary artery: The pulmonic valve is normal in morphology and mobility. No pulmonic insufficiency. Normal RVOT velocity; laminar flow.
Pericardium/other: No pericardial or pleural effusion noted. No obvious cardiac masses.
Heart rhythm: ECG reveals a sinus rhythm with an average HR of 188bpm.

IMAGING

PERFORMED BY

Pamela Harrigan,
RDCS

HOSPITAL NAME

Mass Veterinary
Services

REFERRING VET

Dr. Masloski

INVOICE

32228

DATE

8/8/23

2-Dimensional Measurements

Ao diam (cm)	1.0
LA diam (cm)	1.5
LA:Ao (Swe)	1.5
IVS thickness (cm)	0.52
LVID diastole (cm)	1.7
PW thickness (cm)	0.52
LVID systole (cm)	0.6
FS (%)	66

Doppler Measurements

PV Vmax (m/s)	1.2
AoV Vmax (m/s)	1.5
MR Vmax (m/s)	NA
TR Vmax (m/s)	NA
TR PG (mmHg)	NA

INTERPRETATION OF THE FINDINGS

Compared to the prior study, findings are similar. The LA dimension is stable, and the LV wall thickness remains borderline. No additional issues have developed.

Given these findings, no medications are indicated. Prognosis is guarded, although serial exams showing stable disease is certainly a good sign.



PATIENT

Mojo Romano

SPECIES

Feline

BREED

DSH

SEX

Male Neutered

AGE

6 years

WEIGHT

15.06lbs

INTERPRETED BY

Maggie Machen
Lamy, DVM
DACVIM (Cardiology)

IMAGING

PERFORMED BY

Pamela Harrigan,
RDCS

HOSPITAL NAME

Mass Veterinary
Services

REFERRING VET

Dr. Masloski

INVOICE

32228

DATE

8/8/23

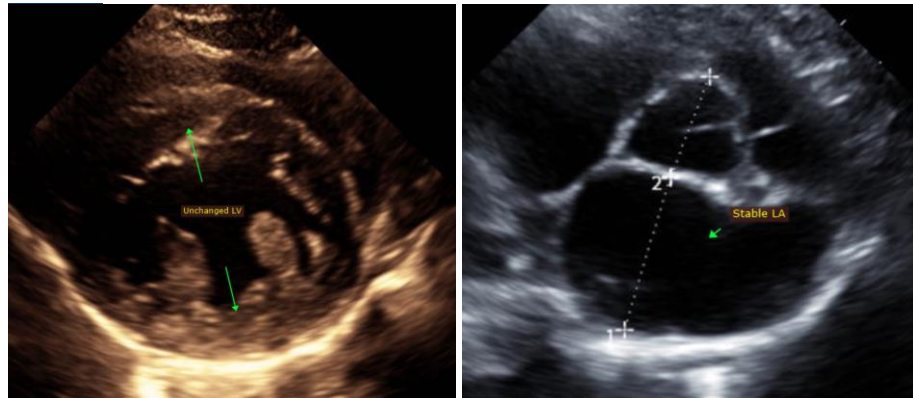
RECOMMENDATIONS

- Given these findings, no medications are indicated.
- Monitor BP/T4 every 6 months.
- Anesthetic risk is considered moderately elevated, however judicious IV fluid rates are advised to avoid fluid overload. Additionally, drugs that stimulate heart rate should be avoided unless clinically necessary (glycopyrrolate, atropine). Avoid vasodilators as this may worsen the obstruction. A reasonable protocol includes opioid/benzodiazepine premedication, propofol induction, and isoflurane maintenance. Additionally, steroids should be used with caution on older cats, as even a 'normal' geriatric heart can develop evidence of intolerance and fluid retention. Monitor at home for signs of cardiac compromise, including respiratory changes and/or signs of a blood clot event (paralysis, neurologic changes).

PLAN

- Recommend recheck echocardiogram in 1 year to assess for any progressive issues or development of disease the pre-existing murmur may mask.

IMAGES



The information and recommendations provided are based on the images presented by the referring veterinarian. No evaluation can be communicated regarding pathology that was not visible in the image/video clips provided.

Thank you for this referral. This report was generated using transcription software, and minor dictation errors may be present. If the clinical or image interpretation does not parallel your findings or if I can be of any further assistance, please contact me.

Maggie Machen Lamy, DVM
Diplomate of the American College of Veterinary Internal Medicine (Cardiology)
info@sonopath.com

Echocardiogram performed by: Pamela Harrigan, RDCS
Pet Animal Ultrasound Service (4paus.com)